

# Pathophysiology and Pathogenesis of Neurofibromatosis Type 1 (NF-1); A Focus on Peripheral Neurofibromas

Brandon Truong, Faculty of Health and Medical Sciences, University of Adelaide

## Aim of Poster

The aim of this poster is to develop of deeper understanding of the mechanisms which cause neurofibromatosis type-1 on a cellular level but also explore the clinical manifestations which may arise from this disorder. Specifically, a focus will be placed behind the biology of peripheral neurofibromas.

## An Introduction to NF-1

- NF-1 is an inheritable multisystem neurocutaneous disorder which affects the skin, nervous system and eyes (Johns Hopkins Medicine, 2018). NF-1 is characterized as an autosomal dominant disorder and is the most prevalent neurocutaneous syndrome affecting every 1 in 2600-3000 individuals (Rasuli, 2020) (Doung et al., 2011).
- NF-1 mainly affects cells derived from the neural crest e.g., Schwann cells, melanocytes and fibroblasts (Trainor et al., 2014).

## Genetic Cause of NF-1

- NF-1 is the result of predisposing mutations occurring at the NF-1 gene which has locus 17q11.2 (refer table 1). The gene product, neurofibromin, is a GTP-ase-activating protein that suppresses the Ras-pathway (Bergoug et al., 2020) (refer figure 1).
- Mutations in the genetic code of the NF-1 gene result in nil production or inhibited function of the neurofibromin protein leading to elevated Ras-GTP levels. Raised levels of active Ras stimulate Raf, MEK and ERK kinases which are responsible for cell growth, proliferation and differentiation (Kang et al., 2019).
- Abnormalities of the NF-1 gene thus results in dysplasia and neoplasia leading to tumour formation (Rasuli, 2020).

## Clinical Manifestations of NF-1

- The clinical manifestations of NF-1 can be identified by 3 main stages, where the manifestations are progressive with each stage (refer figure 2) (BMJ, 2018).
  - Stage 1 [Features]** – this stage involves the manifestations which are directly correlated to the mutation of the NF-1 gene. Examples include café-au-lait macules, neurofibromas, vertebral dysplasia.
  - Stage 2 [Consequences]** – this stage involves symptoms derived from stage 1 manifestations. For example, scoliosis is a derived from vertebral dysplasia.
  - Stage 3 [Complications]** – this stage involves symptoms derived from stage 2 manifestations. For example, scoliosis leading to spinal cord compression.

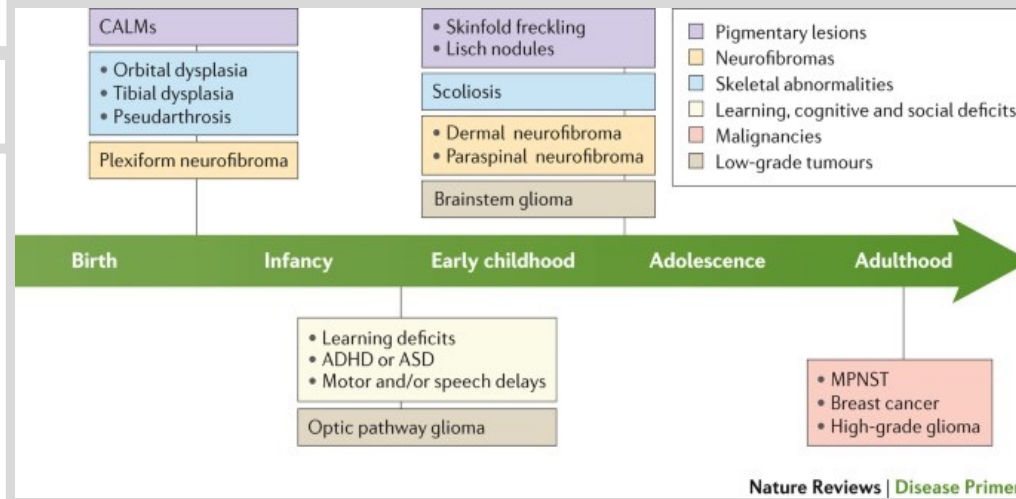


Figure 2: Progression of clinical manifestations of neurofibromatosis type 1. Clinical manifestations worsen from left to right (Gutmann, 2017).

- A clinical criterion exists to successfully diagnose a patient with NF-1. For a diagnosis to be made, at least 2 of 7 criteria need to be met. Clinical manifestations which signify a possible diagnosis of NF-1 are as follows (Hsieh, 2020):
  - >6 café-au-lait macules of >5mm (prepubescent) and >15mm (postpubescent) greatest diameter
  - >2 neurofibromas OR 1 plexiform neurofibroma
  - Axillary/inguinal freckles
  - Optic Glioma
  - >2 Lisch nodules
  - Sphenoid dysplasia/Long-bone abnormalities
  - First-degree relative with NF-1
- Other manifestations of NF-1 can include (Howell et al., 2017):
  - Greater risk of various cancers e.g., gastrointestinal, breast cancers
  - Renal artery stenosis
  - Osteoporosis
  - Congenital heart disease
  - Delayed puberty
  - Macrocephaly

## Biology of Peripheral Neurofibromas

- The formation of benign and malignant tumours increases in incidence throughout the life of an individual with NF-1 (Seminog, 2015).
- Peripheral neurofibromas are benign peripheral nerve-sheath tumours which can present under the skin or deeper regions of the body and nerve roots exiting the central nervous system.
- These tumours form centrally within the nerve are made up of a unique composition of Schwann cells, fibroblasts, disrupted perineurial cells and mast cells (refer figure 3) (Ortonne et al., 2018).
- Schwann cells have been identified as the primary tumour cell of NF-1-associated neurofibromas due to nil discovery of NF-1 alleles in these cells and their neural crest origin (Maertens et al., 2006).
- There are three types of peripheral neurofibromas all of which are neoplasms of Schwann cells:
  - Cutaneous/dermal neurofibromas (cNF)** – present as soft discoloured lumps on the skin. (Tonsgard, 2006).
  - Plexiform neurofibromas (pNF)** – located superficially and on minor nerves and large nerves. May convert into malignant peripheral nerve sheath tumours (Dombi et al., 2007).
  - Nodular neurofibromas (nNF)** – present as distinct, hard and tough lesions that grow under the dermis which may enlarge. nNF may become precancerous tumours (Miettinen, 2017).
- These tumours can present as clinically harmless or may compress surrounding nerves and tissues leading to damage (Brazier, 2018).

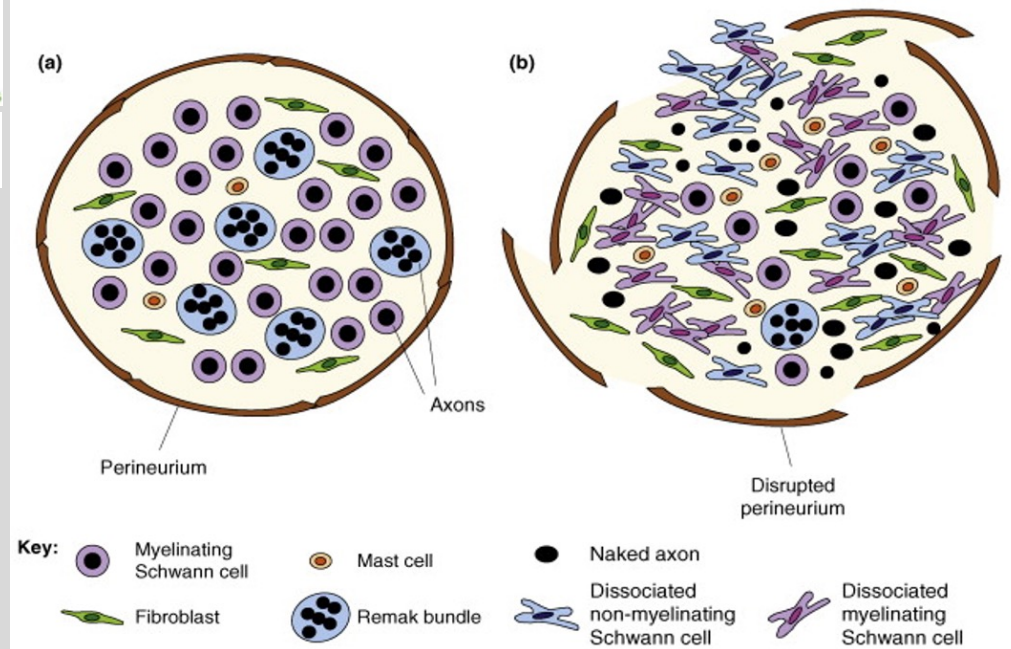


Figure 3: Diagram depicting (a) a healthy single nerve fascicle and (b) the composition of a single nerve fascicle in neurofibromas (Parrinello, 2009).

## Conclusion

- NF-1 is a multi-system neurocutaneous disorder caused by phenotypic variations at the NF-1 gene.
- Clinical manifestations of NF-1 are widespread and can be split into three progressive stages
- Peripheral neurofibromas are normally benign however, there is potential for a malignant transformation.
- Although no cure exists for NF-1 yet, many treatments for symptoms are available such as surgical removal of tumours, chemo/radiation therapy and medications. A major clinical trial in progress to test the drug Tipifarnib which is hypothesized to inhibit the Raf, MEK, ERK pathways.

Mutation	Notes
Small deletion	Removal of a small number of DNA bases, usually leading to failure of protein production
Premature "stop" mutation	Changing the genetic instructions to insert an amino acid to a sequence that causes production of the protein to stop
Deletion of multiple exons	Can result in either shortening of the protein or complete failure of production
Amino acid substitution	May alter the structure or function of the protein
Small insertion	Has similar impact as small deletion
Mutation of an intron (noncoding section of a gene)	Interferes with the splicing process, resulting in an abnormal protein, or no protein produced at all
Deletion of entire gene	Complete gene deletion results in no protein product from that gene copy
Chromosome abnormality	A rearrangement of the structure of a chromosome can disrupt a gene, such as NF1
Alteration of the 3' untranslated region	Unclear if changes that follow the coding sequence of the NF1 gene are really mutations or incidental changes
Large insertion	Has similar impact as large deletions

Table 1: Types of pathogenic variants in the NF-1 gene with potential to disrupt normal synthesis of the gene product, neurofibromin leading to neurofibromatosis type 1 (Rubenstein, 2005).

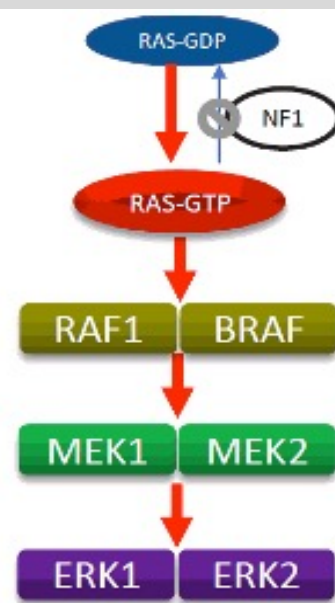


Figure 1: Diagram presenting greater activity of the Ras pathway due to suppression of NF-1 gene (Kang, 2019).

# References

- Bergoug, M. et al. (2020) "Neurofibromin Structure, Functions and Regulation", *Cells*, 9(11), p. 2365. doi: 10.3390/cells9112365.
- BMJ. (2021) *UA Sign-On*, *Bestpractice-bmj-com.proxy.library.adelaide.edu.au*. Available at: <https://bestpractice-bmj-com.proxy.library.adelaide.edu.au/topics/en-gb/410/diagnosis-approach> (Accessed: 3 April 2021).
- Britannica, 2020. *Schwann cell | Definition, Function, & Facts*. [online] Encyclopedia Britannica. Available at: <<https://www.britannica.com/science/Schwann-cell>> [Accessed 4 April 2021].
- Dombi, E. et al. (2007) "NF1 plexiform neurofibroma growth rate by volumetric MRI: Relationship to age and body weight", *Neurology*, 68(9), pp. 643-647. doi: 10.1212/01.wnl.0000250332.89420.e6.
- Duong, T. et al. (2011) "Mortality Associated with Neurofibromatosis 1: A Cohort Study of 1895 Patients in 1980-2006 in France", *Orphanet Journal of Rare Diseases*, 6(1), p. 18. doi: 10.1186/1750-1172-6-18.
- Gutmann, D. et al. (2017) "Neurofibromatosis type 1", *Nature Reviews Disease Primers*, 3(1). doi: 10.1038/nrdp.2017.4.
- Howell, S. et al. (2017) "Increased risk of breast cancer in neurofibromatosis type 1: current insights", *Breast Cancer: Targets and Therapy*, Volume 9, pp. 531-536. doi: 10.2147/bctt.s111397.
- Hsieh, D., 2020. *Neurofibromatosis Type 1: Practice Essentials, Background, Pathophysiology*. [online] Emedicine.medscape.com. Available at: <<https://emedicine.medscape.com/article/1177266-overview>> [Accessed 24 April 2021].
- Kang, E. et al. (2019) "Phenotype categorization of neurofibromatosis type I and correlation to NF1 mutation types", *Journal of Human Genetics*, 65(2), pp. 79-89. doi: 10.1038/s10038-019-0695-0.
- Maertens, O. et al. (2006) "ComprehensiveNF1 screening on cultured Schwann cells from neurofibromas", *Human Mutation*, 27(10), pp. 1030-1040. doi: 10.1002/humu.20389.
- Miettinen, M. et al. (2017) "Histopathologic evaluation of atypical neurofibromatous tumors and their transformation into malignant peripheral nerve sheath tumor in patients with neurofibromatosis 1—a consensus overview", *Human Pathology*, 67, pp. 1-10. doi: 10.1016/j.humpath.2017.05.010.
- Ortonne, N. et al. (2018) "Cutaneous neurofibromas", *Neurology*, 91(2 Supplement 1), pp. S5-S13. doi: 10.1212/wnl.0000000000005792.
- Parrinello, S. (2009) "Neurofibroma development in NF1 – insights into tumour initiation", *Trends in Cell Biology*, 19(8), pp. 395-403. doi: 10.1016/j.tcb.2009.05.003.
- Rasuli, B. (2020) *Neurofibromatosis type 1 | Radiology Reference Article | Radiopaedia.org*, *Radiopaedia.org*. Available at: <https://radiopaedia.org/articles/neurofibromatosis-type-1> (Accessed: 15 April 2021).
- Rhodes, S. et al. (2019) "Cdkn2a (Arf) loss drives NF1-associated atypical neurofibroma and malignant transformation", *Human Molecular Genetics*, 28(16), pp. 2752-2762. doi: 10.1093/hmg/ddz095.
- Rubenstein, A., 2005. *Neurofibromatosis: A Handbook for Patients, Families, and Health Care Professionals*. 1st ed. Stuttgart: Georg Thieme Verlag, p.30.
- Seminog, O. (2015) "Age-specific risk of breast cancer in women with neurofibromatosis type 1", *British Journal of Cancer*, 112(9), pp. 1546-1548. doi: 10.1038/bjc.2015.78.
- Tongard, J. (2006) "Clinical Manifestations and Management of Neurofibromatosis Type 1", *Seminars in Pediatric Neurology*, 13(1), pp. 2-7. doi: 10.1016/j.spen.2006.01.005.
- Trainor, P., 2014. *Neural Crest Cells: Evolution, Development and Disease*. 1st ed. Elsevier. Boston, U.S. A.