

## Gastric Perforation by Fish Bone Case Report

### Abstract

### Introduction

The ingestion of foreign bodies is usually accidental and asymptomatic due to the non-specificity of the symptoms, it is observed more frequently in patients with psychiatric illnesses, children and elderly people.

### Case presentation

A 70-year-old male patient attended the emergency due to pain of high intensity localized in the epigastrium, with the presence of a palpable, painful mass with irregular edges.

### Discussion

Only in 23% of the cases the preoperative diagnosis is obtained, therefore, it is necessary to consider the epidemiological antecedents, perform laboratory tests, image evaluation and correct physical examination, since this can be confused with tumors, for example, pancreatic head carcinoma.

### Conclusion

The perforation caused by ingestion of fishbone is observed only in 1% of the cases and the diagnosis is usually confirmed during the surgical act, in retrospective the interrogation always throws information so it should be taken into account before lesions collections or abscesses abdominals of doubtful etiology.

### Introduction

80-90% of foreign bodies ingested are digested and expelled without causing symptoms; of the remaining percentage depending on the shape and size less than 1% remain in the stomach and can cause a perforation and affect adjacent organs such as the pancreas [1]. This is usually manifested as an intra-abdominal abscess in 71% of cases with clinical manifestations at days and even weeks after ingestion and whose etiology is a mystery for the surgical team. Although these patients are studied exhaustively with radiological and endoscopic techniques, it is not until the very surgical act where the final diagnosis is made, and when generally very aggressive approaches have been made [2,3]. In the present article, we report the case of a patient who presented with a palpable abdominal mass in the epigastrium who was diagnosed and

### Open Access

### Case Report

**Pedro Monsalve, Gabriela Lombardo P and Elaine Bastardo\***


Department of plastic Surgery Service, Venezuela

#### \*Address for Correspondence

Pedro Monsalve, Caracas University Hospital at the Service of General Surgery II, Venezuela

**Submission:** September 23, 2019

**Published:** October 03, 2019

**Copyright:** ©  This work is licensed under Creative Commons Attribution 4.0 License

initially treated as a pancreatic head tumor, and after performing a diagnostic laparoscopy showed a perforation by a fishbone.

### Case Report

A 70-year-old male patient consulted for abdominal pain of progressive intensity in the epigastrium and multiple febrile hooks of 39 °C. Physical examination shows a loss of 2.5Kg compared to his usual weight and a flat abdomen not irritated but painful to deep palpation in the epigastrium with a mass of ill-defined edges of approximately 6cm in diameter. Laboratory tests showed leukocytosis with deviation to the left, with elevation of alkaline phosphatase (ALP) without alteration of the rest of the hepatobiliary profile, amylase / lipase, with serologies and negative tumor markers (CA-19-9, CEA, and AFP).

In the ecosonogram (*Figure 1*), a cystic-looking image with low-level echoes in its interior, approximately 20x13mm in diameter, was evidenced in the head of the pancreas, while in the double-contrast tomography (*Figure 2*) it was observed a space-occupying lesion behind the posterior gastric wall towards the omentum recess, adjacent to the hypodense pancreatic head, with ill-defined edges, with attenuation coefficients within the solid and liquid range of approximately 5.6x5.6cm diameter. On the other hand, upper gastrointestinal endoscopy showed a rounded lesion that pushed the posterior aspect of the cardia. A puncture was made and a purulent fluid was drained from which sample was taken for cytology and culture, which turned out to be an inflammatory exudate with abundant polymorphonuclears and basophil bacterial aggregates (*Actynomices*). The patient is managed with medical treatment and antibiotic therapy for several weeks, however when there is no evidence of improvement and in view of the persistence of the symptoms, a diagnostic laparoscopy was planned. During the surgical act, the insertion of the greater omentum was dissected with the greater gastric

curvature to access the transcavity of the omentum and a foreign body was found that came from the stomach, perforating the posterior wall and making contact with the head of the pancreas (Figure 3). It was removed and after a cavity aspiration and washing, the surgery was completed.

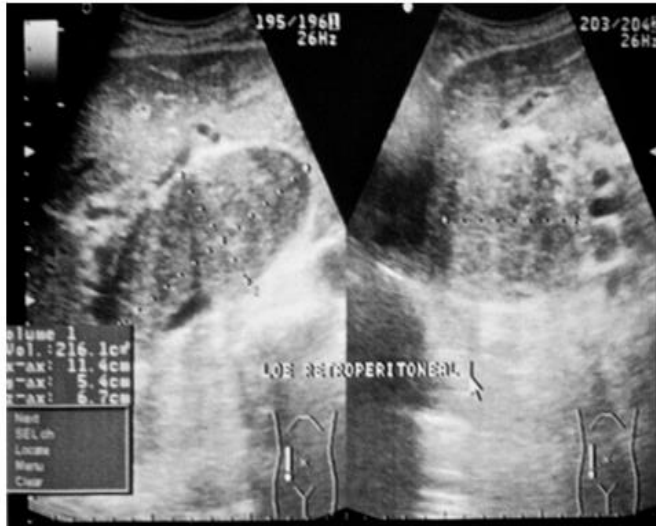


Figure 1.

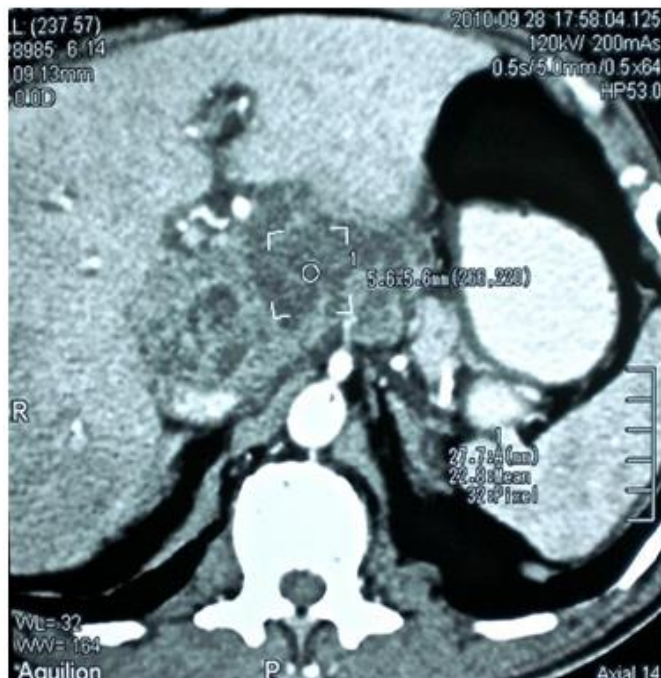

Figure 2.

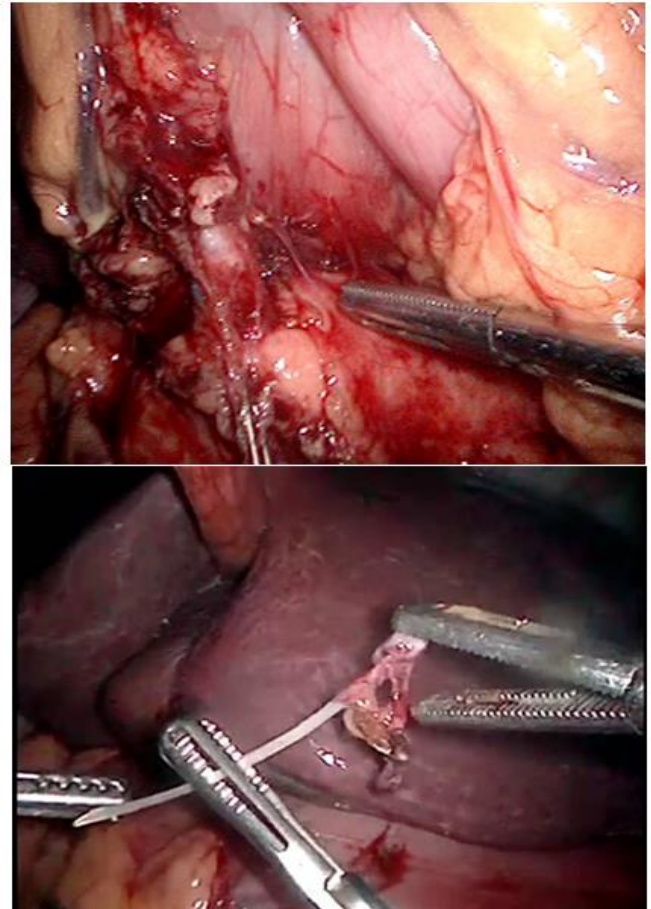


Figure 3.

When the foreign body was examined, it was determined that it was a fishbone, information that was later corroborated by the same patient when he was re-interrogated and even retrospectively diagnosed in the tomography performed. The patient presented immediate improvement, progressed satisfactorily and was discharged.

### Discussion

The unconscious ingestion of foreign bodies usually comes from food, and almost two thirds of these are: fish bones, chicken bones and rinds [4]; most go through the gastrointestinal tract (GIT) without manifestations in about 1 week and complications, such as perforations, are not common [5], therefore the diagnosis is difficult; In up to 23% of the cases, the correct preoperative diagnosis is made, the other cases being confused with pancreatic carcinoma, acute cholecystitis, appendicitis, diverticulitis, intestinal obstruction, gastric stromal tumors (GIST) or even an incarcerated

hernia[6-8]. The symptomatology is non-specific and clinically it can present as an acute abdomen, peritonitis, intra-abdominal abscesses, fistulas, among others [9]; in addition, patients do not refer or remember the intake of foreign bodies, there may even be a considerable period of time (months, years) between the intake and the appearance of symptoms, which is why it is considered that at some point these cases will require a surgical approach [10].

For the differential diagnosis it is necessary to thoroughly investigate the medical and epidemiological antecedents of the patient, the physical examination along with the anamnesis, the results of the evaluation by image, laboratory tests and analysis of selective tumor markers such as AFP, CA 19-9 and CEA; The most commonly used tumor marker to identify a pancreatic neoplasm is CA 19-9 [11]. Liver enzymes are usually within normal or occasionally elevated limits. The people with greater risk are patients with psychiatric illnesses such as schizophrenia and depression, also alcoholics, children and the elderly [7-9]; It is also seen in dental prosthesis carriers that present desensitization of the palate [4]. Most perforations occur in the angulated areas, such as, cisura angularis, rectosigmoid junction, pyloric region, duodenum or ileocecal valve, although they have also been reported in other organs such as the bladder and liver [1,12,13]. In this case, the patient presented only leukocytosis with an increase in ALP.

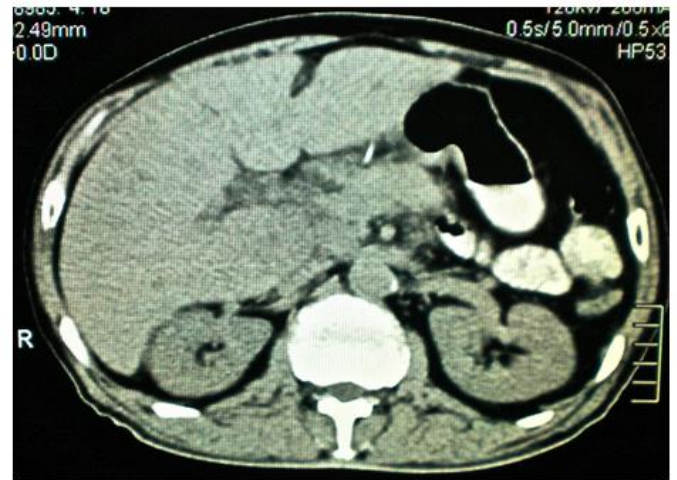Three mechanisms have been postulated to explain the perforation of foreign bodies:

- a) The small and sharp body is pushed through the wall with minimal necrosis;
- b) The body produces an area of necrosis that migrates through the wall of the viscus;
- c) The foreign body produces an area of necrosis that perforates secondarily after the object has crossed the wall;

However, the foreign body does not necessarily have to pass through the wall to perforate it, but a process of necrosis and pressure of the wall occurs [5]. Gastric perforations are usually observed in the lesser curvature, the foreign body can partially perforate the wall causing inflammatory changes and subsequently a perigastric abscess; In some cases, a liver abscess can form when the anterior gastric wall penetrates completely or the first portions of the duodenum that are in contact with the left hepatic lobe [14]. It has been shown that spines wider than 2cm and greater than 5cm in length usually stay housed inside the gastric cavity [3].

The first abscess on account of foreign body was reported by Lambert in 1898, [15] and since then many cases have been documented including those caused by fishbone; The first case of secondary pancreatic mass due to foreign body migration (fishbone) was described by Goh et al; in this study they postulate, as in our case, that the fishbone perforated the posterior gastric wall and migrated to the pancreas forming an abscess; in retrospect, they observed a radiopaque image on the CT scan that turned out to be the spine and not a blood vessel,

in the same way we could verify it in the study of our patient prior to the administration of the contrast (Figure 4) [16].



**Figure 4.**

In this article the authors did not suspect the foreign body ingestion for several reasons:

- a) The patient did not refer it in the interrogation;
- b) The patient was afebrile;
- c) There was no leukocytosis; and
- d) The diagnosis of pancreatic mass by foreign body had not been described.

However, in this case, our patient had some indications that could have guided the diagnosis:

- A) Fish was part of his usual diet;
- B) Fever was always present;
- C) There was leukocytosis and
- D) There are already some similar cases described in the literature.

The second case was also described by Goh et al in a 32-year-old patient with peritoneal irritation and leukocytosis who was taken on a surgical shift for an emergency laparotomy where an abscess involving the duodenum, head of the pancreas and the caudate lobe of the liver, caused by a fishbone that perforated the duodenum. In this case the drainage and antibiotic therapy were the applied treatment [17].

The third case described was by Yasuda et al in a 73-year-old patient with abdominal pain and leukocytosis, with elevated CRP who developed peritonitis and who underwent an emergency exploratory laparotomy where it was found that a 4cm fishbone penetrated the first portion of the posterior duodenal wall towards the head of the pancreas [18]. Bajwa, described the first case of a lesion similar to a GIST in the posterior gastric wall that, when removed in a distal

gastrectomy, reported an inflammatory infiltrate around a fishbone in the histological study [19].

A prospective study of 358 patients who ingested fish bones showed that the use of simple radiographs to make the diagnosis is not reliable (32%) and depends on the degree of radiopacity of the fish bone, which is usually very low. The tomography on the other hand has been more sensitive in the initial evaluation (71.4%) with improvement to 100% in retrospective evaluations; revealing the spine as a linear calcification, however there must be a high suspicion [20]; The main limitation of CT is the lack of suspicion of the observer [13].

Recent studies have shown that mortality due to liver abscess is approximately 11-33% and the causative agent responsible for the most frequent inflammatory process is *Streptococcus*, however, in most cases it is unknown [21]. When upper gastrointestinal endoscopy was performed, the lesion was observed on the posterior aspect of the cardia, in contact with the gastric wall, body of the pancreas and left hepatic lobe; in the cytomorphological findings according to the observed characteristics, compatibility with *Actinomyces* was obtained.

## Conclusion

Although practically all ingested foreign bodies are eliminated asymptotically, it should be taken into account that 1% of cases cause perforations, and these usually affect mainly the stomach, pancreas or liver; therefore, this possibility should be considered in the case of abdominal sepsis, collections or suspicious abscesses (and particularly in infections by atypical germs). It is a difficult diagnosis that usually emerges as a differential only if the suspicion is raised and although the exhaustive interrogation usually provides important data it is in the surgical time where this suspicion is confirmed. With this in mind, it is possible to plan a minimally invasive approach and avoid counterproductive results derived from aggressive behaviors.

## References

- Nunez Martinez O, Sanz Garcia C, Perez Enciso I, Holguera Ortiz L, Alberdi Alonso JM (2017) Endoscopic resolution of gastric perforation with pancreas penetration by a fish bone. *Gastroenterol Hepatol* 41(19): 567-568.
- Huang YH, Siao FY, Yen HH (2013) Pre-operative diagnosis of pancreatic abscess from a penetrating fish bone. *Qjm* 106(10): 955-956.
- Koch H (1977) Operative endoscopy. *Gastrointest Endosc* 24: 65-68.
- Velitchkov NG, Grigorov GI, Losanoff JE, Kjossev K (1996) Ingested foreign bodies of the gastrointestinal tract: retrospective analysis of 542 cases. *World J Surg* 20: 1001-1005.
- Daniell SJ (1982) Foreign body perforation of a jejunal diverticulum. *Journal of the Royal Society of Medicine* 75: 747-749.
- Maleki M, Evans W (1970) Foreign-body perforation of the intestinal tract. Report of 12 cases and review of the literature. *Arch Surg* 01: 474-477.
- Kim SW, Song SK (2014) Gastric pseudotumoral lesion caused by a fish bone mimicking a gastric submucosal tumor. *J Gastric Cancer* 14(3): 204-206.
- Beecher SM, O'Leary DP, McLaughlin R (2015) Diagnostic dilemmas due to fish bone ingestion: Case report & literature review. *Int J Surg Case Rep* 13: 112-115.
- Mesina C, Vasile I, Valcea DI, Pasalega M, Calota F, et al. (2013) Problems of diagnosis and treatment caused by ingested foreign bodies. *Chirurgia* 108(3): 400-406.
- Ali FE, Al-Busairi WA, Esbaita EY, Al-Bustan MA (2005) Chronic perforation of the sigmoid colon by foreign body. *Curr Surg* 62(4): 419-422.
- Wang WG, Zhang Y, Wang L, Chen Y, Tian BL (2015) Chronic pancreatic inflammatory granuloma caused by foreign body presenting as a pancreatic pseudotumor: A case report and literature review. *Pancreatol* 15(5): 573-575.
- Sierra-Ruiz M, Saenz-Copete JC, Enriquez-Marulanda A, Ordonez CA (2016) Extra luminal migration of ingested fish bone to the spleen as an unusual cause of splenic rupture: Case report and literature review. *Int J Surg Case Rep* 25: 184-187.
- Goh BK, Tan YM, Lin SE, et al. (2016) CT in the preoperative diagnosis of fish bone perforation of the gastrointestinal tract. *AJR Am J Roentgenol* 187(3): 710-714.
- Paixao TS, Leao RV, de Souza Maciel Rocha Horvat N, et al. (2017) Abdominal manifestations of fishbone perforation: a pictorial essay. *Abdom Radiol* 42(4): 1087-1095.
- Lambert A (1989) Abscess of the liver of unusual origin. *NY Med J* 1898:177-8.
- Goh BK, Jeyaraj PR, Chan HS, Hock-Soo Ong, Thirvgnanam A, et al. (2004) A case of fish bone perforation of the stomach mimicking a locally advanced pancreatic carcinoma. *Dig Dis Sci* 49(11): 1935-1937.
- Goh BK, Yong WS, Yeo AW (2005) Pancreatic and hepatic abscess secondary to fish bone perforation of the duodenum. *Dig Dis Sci* 50(6): 1103-1106.
- Yasuda T, Kawamura S, Shimada E, Okumura S (2010) Fish bone penetration of the duodenum extending into the pancreas: report of a case. *Surg Today* 40(7): 676-678.
- Bajwa A, Seth H, Hughes F (2007) Ingested fishbone mimicking a gastric submucosal tumour. *Grand Rounds* 7: 42-44.
- Ngan JH, Fok PJ, Lai EC, Branicki FJ, Wong J (1990) A prospective study on fish bone ingestion. Experience of 358 patients. *Ann Surg* 211(4): 459-462.
- Bandeira-de-Mello RG, Bondar G, Schneider E, Wiener-Stensmann IC, Gressler JB, Krueel CRP (2018) Pyogenic Liver Abscess Secondary to Foreign Body (Fish Bone) Treated by Laparoscopy: A Case Report. *Ann Hepatol* 17(1): 169-173.

**Assets of Publishing with us**

Global archiving of articles  
Immediate, unrestricted  
online access Rigorous Peer  
Review Process Authors  
Retain Copyrights

<https://www.biomedress.com>

**Submission Link:** <https://biomedress.com/online-submission.php>