

A Young Man Dying Of Fulminant Hepato-Renal Syndrome

The Tagging To Alcohol Addiction Obscured the Diagnosis and Precluded the Treatment of Chronic Viral Hepatitis (HBV, HCV, HDV) As the Cause of His Liver Cirrhosis

Kari Syrjänen^{1*}, Pentti Sipponen², Matti Härkönen³ and Hannes Tamm⁴

¹Molecular Oncology Research Center, Barretos Cancer Hospital, Barretos SP, Brazil

²Patolab Oy, Medical Laboratories, Espoo, Finland

³Department of Clinical Chemistry, University of Helsinki, Finland

⁴Department of Pathology and Forensic Medicine, Tartu University Hospital, Tartu, Estonia

Received: April 20, 2017; Accepted: May 24, 2017; Published: May 30, 2017

*Corresponding author: Kari Syrjänen, Molecular Oncology Research Center, Barretos Cancer Hospital, Barretos SP, Brazil, Tel: +55-17-8806-5644; Fax: +55-17-3321-6600; E-mail: kasyrja@hcancerbarretos.com.br

Abstract

Discourse: The present report describes a 47-year-old man who was referred to hospital due to liver cirrhosis and acute hepato-renal syndrome (HRS) that rapidly progressed, and of which he died within two months. As a result of a sequence of unfortunate events in his management, including an inaccurate and in part erroneous record of the patient's past history, alcohol was considered as the sole cause of the liver failure (ALD), importantly, without taking a liver biopsy. The patient was ranked outside curative therapy, including renal replacement therapy (RRT) as the bridge to eventual liver transplantation. Instead, he received two courses of corticosteroids (for ALD). The negative serology for hepatitis viruses was not controlled, until in the other hospital during the final days before death, when the patient tested positive for HBV (HBsAb).

Autopsy: At autopsy, the liver was large (2.800 g) with micronodular cirrhosis but no typical signs of ALD. When examined using immunohistochemistry (IHC), liver cells were extensively loaded with HBV, HCV and HDV, implicating an activation of a latent chronic viral hepatitis during the hospitalization, and massive replication of all three hepatotropic viruses. This activation, remaining unnoticed by the clinicians, obviously resulted in acute-on-chronic fulminant viral hepatitis with rapid and fatal liver failure.

Conclusions: By labeling the patient's liver failure as ALD obscured adequate search for other potential causative factors for the patient's HRS. This is most unfortunate, because standard curative medical treatments (DAA, direct acting antivirals) are available for viral hepatitis, and their diagnosis by biopsy should be straightforward. In contrast, treatment with steroids is contraindicated in viral hepatitis.

Introduction

The present report describes a 47-year-old man who was referred to hospital due to cirrhosis and acute hepato-renal syndrome (HRS) that rapidly progressed, and of which he died within two months. Alcohol was considered as the sole cause of the liver failure (ALD). Because of this, the patient was ranked outside of curative therapy; i.e., intensive care for HRS, treatment with molecular adsorbent recirculating system (MARS), as well as renal replacement therapy (RRT) as the bridge to eventual liver transplantation [1-6]. In addition to conservative treatment, the patient only received two courses of corticosteroids (methylprednisolone). At hospital entry, HBV (HBsAg) and HCV (HCAb) were tested as negative. Viral serology was not re-evaluated until in the other hospital during the final days before death, when the patient tested positive for HBV (HBsAb).

At autopsy, the liver was large with micronodular cirrhosis, but the characteristic signs of ALD were not found. When examined using immunohistochemistry (IHC), liver cells were extensively loaded with HBV, HCV and HDV, implicating an activation of latent chronic viral hepatitis during the hospitalization, and massive replication of all three hepatotropic viruses. This activation, remaining completely unnoticed by the clinicians, obviously resulted in acute-on-chronic fulminant viral hepatitis with rapid and fatal liver failure.

In this case, the sticking to alcohol as a sole reason to the liver failure obscured adequate search for other potential causative factors for the patient's HRS. This is most unfortunate,

because standard curative medical treatments (interferons and later, DAA; direct-acting antivirals) have been available for viral hepatitis since the 1980's [7,8], and their diagnosis by serological and other tests (biopsy) should be straightforward, provided that potential sources of false negative results had been kept in mind [9-12]. In contrast, treatment with steroids is contraindicated in viral hepatitis [13,14].

Case History

Private practitioner

The discourse starts in 2009 when the 45-year-old man (active paramedical professional) was treated by a private doctor for severe pains diagnosed as arthrosis of the right hip, associated with obesity. While being evaluated for hip surgery (March 2010), the temporal use of alcohol was recorded, accompanied by abnormal liver function tests. Multi-drug medication (polypharmacy) with painkillers was prescribed, being continued throughout 2010, with no appointment to the doctor until in April 2011.

City hospital (CH)

On November 2, 2011, the patient visited his private doctor for acute jaundice. Because of ascites and deep jaundice, he was referred as an emergency to a local city hospital (CH). In emergency room (at night), an accurate recording of his past history failed expect the recordings of alcohol consumption. The official hospital records stated: a) no travels abroad, b) no regular medication, c) no herbal remedies (all untrue). As mentioned above, he had used polypharmacy since 2009 (several painkillers, including opiate plasters). In addition, he was a regular user of a food supplement (Tonalin® CLA Strong), which is known for its potent liver-toxic effects [15-17]. Since the very beginning, however, the patient was hospitalized with the diagnosis of acute liver failure of alcohol etiology (alcohol related liver disease; ALD), and the symptomatic medication was instituted.

Liver ultrasound at hospital entry showed an enlarged, nodular and cirrhotic liver, but not ascites. The liver disease was labeled as an ALD, for which the prednisone treatment 40 mg daily lasting from November 4 to December 3 was instituted. Ursodeoxycholic acid (Adursal) was initiated for liver protection. In blood samples drawn on 3rd November, he was tested negative for HBsAg, HCVAb, EBV-Ab (IgG, IgM), and CMVAb (IgG, IgM), implicating the absence of serological signs of an on-going viral hepatitis [18,19]. Also, anti-nuclear antibodies were negative, excluding the autoimmune hepatitis. However, no liver biopsies were taken to confirm the diagnosis of ALD and/or to exclude the other potential causes of the liver failure, most notably viral hepatitis, toxic drug reactions, and obesity-associated fatty liver.

At control visit on November 15th, no significant improvement was evidenced in the clinical condition; jaundice persisted. A specialist at the Department of Gastroenterology (DG) at UH was consulted for the possible therapeutic options, with special reference to liver transplantation. According to her written testimonial (November 23rd), the patient was not

considered eligible for liver transplantation, based on i) overall evaluation of his current status, ii) short period of alcohol abstinence (4-5 weeks according to the patient's testimony), and iii) ALD as the course of his HRS. On November 23, a new abdominal ultrasound disclosed abundant ascites.

University hospital (UH)

The hospitalization at UH started on December 6th, when the patient was referred to UH from the CH because of aggravated symptoms. Symptomatic conservative treatment was continued and instituted at UH, including administration of telipressin, to alleviate acute symptoms [1-6]. Based on consultation with liver surgeons, the decision to refrain from RRT was maintained. He was considered ineligible for liver transplantation, as previously explained, due to the labeling as an alcohol addict with acute-on-chronic ALD. Importantly, this diagnosis was never confirmed by liver biopsy at UH.

The potential causes of liver damage other than alcohol were considered only on December 8, including infections (not defined in the records) and liver-toxic medications. The conclusion, however, was that the cause of the liver failure was alcoholic cirrhosis and alcohol hepatitis which had progressed to HRS. According to the written statement of December 8, 2011, the patient was not considered eligible for liver transplantation. This conclusion was decisive for the outcome of his remaining time in UH, which, under conservative treatment (and steroids), was characterized by a rapid and fulminant downhill course. It was recorded that the patient does not benefit from an intense care or dialysis, and neither MARS treatment nor liver transplantation were options (December 19th). Instead, a therapy with methyl prednisolone 40mg i.v. was initiated again on December 17th.

University hospital abroad

Not satisfied with the conservative treatment strategy, patient's parents decided to transfer him to another UH in a country nearby, which was realized (by helicopter) on December 22nd. Intense care was initiated immediately upon arrival, including hemodialysis, but the patient died on December 26th, the 5th day of hospitalization. During the five last days, the results of the liver and kidney function tests improved dramatically after onset of dialysis and intense care. Importantly, the patient also tested (for the first time) positive for HBsAb (with no history of HBV-vaccination).

Autopsy findings

Forensic autopsy was performed in the UH abroad, and another one later in Finland (requested by law). The findings in both autopsies were concordant, although the second one was hampered by advanced autolysis. The primary cause of death was cerebral hemorrhage, resulting from the fulminant HRS.

malignancy, history of chronic alcohol intake, history of jaundice, cardiopulmonary disease, morbid obesity, choledocholithiasis, biliary obstruction, cholangitis, carcinoma gallbladder, a recent (< 3 weeks) or ongoing episode of acute gallstone pancreatitis

The organ-specific findings in the two autopsies were consistent with HRS, the condition that was never questioned during the hospitalization. In this case, of main interest are the histological findings of the liver, which was abundantly sampled in the first autopsy. The liver was large, weighting 2800 g, measuring 34x29x9cm, and being micronodular in cross appearance. According to the original autopsy report and in light microscopic examination, the liver disease was considered as micronodular cirrhosis of unclear etiology. A direct citation from the autopsy report: "The process due to the toxic effects of alcohol was not excluded, but characteristic features indicating late adverse effects of alcohol were not observed".

In the second autopsy (January 17, 2012), the initial autopsy findings were confirmed. The liver samples were examined by an expert pathologist, classifying the liver disease as macronodular cirrhosis NOS (not otherwise specified). As in the first autopsy, no signs of steatosis (fatty liver), typical to alcoholic hepatitis and cirrhosis, were not found in the liver samples.

Immunohistochemistry (IHC) of liver samples for hepatotropic viruses

The tissue blocks made from the samples at the first autopsy (No 255/2011) were kindly provided by the pathology department of the UH where the patient deceased. Despite advanced autolysis, intact (cirrhotic) liver tissue was available in the sample, making possible to conduct immunohistochemical (IHC) staining for HBV, HCV and HDV, as well as for EBV (Epstein-Barr Virus) and CMV (Cytomegalovirus); the known agents that induce chronic viral hepatitis. The IHC technique in routine use for paraffin-embedded sections was applied, as detailed elsewhere, and slightly modified for each specific antibody (20). The antibodies for HBV, HCV and HDV were all provided by Nordic BioSite (Täby, Sweden): 1) HBV/HBsAg

<http://www.nordicbiosite.com/products/hbv-hbsag-ls-c312066-100>; (diluted 1:20) 2) HCV Core protein;

<http://www.nordicbiosite.com/products/hcv-core-protein-bs-0221r>; (diluted 1:100) and 3) DIPA (Delta-interacting protein A)

<http://www.nordicbiosite.com/products/dipa-ap9120c-ev>

(diluted 1:75). For demonstration of EBV, a standard immunoperoxidase technique was used with a monoclonal mouse anti-EBV LMP-1 antibody (diluted 1:50; Dako Real™ peroxidase/DAB+ rabbit/mouse kit and LMP-1 antibody), using the DakoTekMate tissue-stainer. For pretreatment, the slides were microwaved in a citrate buffer, pH 6.0 for 5 minutes, twice. Proteinase K pretreatment (10 minutes, Dako Real Proteinase-K ready-to-use kit) was performed using the TekMate. Positive control was a paraffin section from EBV positive NPC. In all negative controls, the primary antibody was omitted. For CMV, the procedure was the same, using the monoclonal mouse antibody clone CCH2 (diluted 1:20; Dako, cat. no. M0757).

The results of the immunostaining for HBV, HCV and HDV are shown in Figure 1. As explained in detail in the Figure

legend, the liver sample clearly expressed all three hepatitis viruses, known to be frequent causes of a chronic liver infection and cirrhosis (HBV, HCV, HDV) [19]. The IHC for CMV and EBV was entirely negative, with no expression of these two hepatotropic viruses in the liver cells (not illustrated in Figure 1).

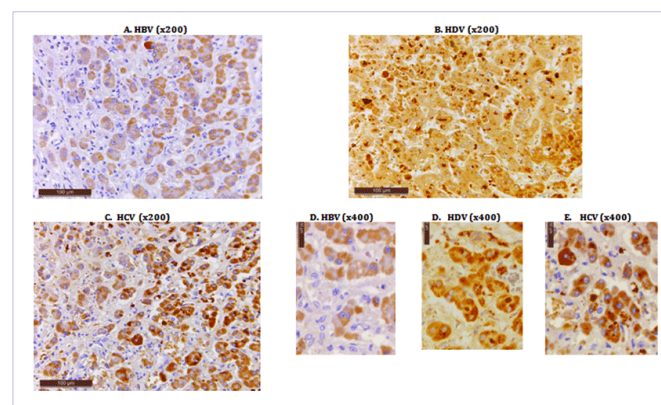


Figure 1: A). A medium power view of a well preserved focus of the patient's autopsy liver sample stained with monoclonal anti-HBV/HBsAg. A diffuse cytoplasmic (light-brown) staining indicating the presence of HBsAg is clearly visible in practically all liver cells of this field of view. (Original magnification x200).

B). The same autopsy sample of the liver stained for delta-interacting protein A (HDV) using monoclonal anti-DIPA antibody. Practically all liver cells within this field contain intensely brown, coarse granular staining signifying the presence of HDV viral protein both in the cytoplasm and within the nuclei. (Original magnification x200).

C). The same liver sample stained for HCV core protein using polyclonal anti-HCVcAg antibody. Most of the liver cells demonstrate an intense brown, coarsely granular staining localizing HCV core protein mostly in the cell cytoplasm. (Original magnification x200).

D). A higher power view of the liver sample demonstrating a diffuse, finely granular cytoplasmic immunostaining for HBsAg. The staining intensity shows some variation, with single cells staining intensely positive (right lower corner). (Original magnification x400).

E). Intense expression of HDV (delta-interacting protein A) is well depicted in this higher-power view of anti-DIPA-stained section. The coarse granular staining (dark brown) signifying the presence of HDV viral protein is mostly cytoplasmic, but a few cells with nuclear staining is present as well. (Original magnification x400).

F). In this higher power view, HCV core protein is abundantly expressed, showing different immunostaining patterns with anti-HCVcAg antibody. Practically all liver cells are positive, showing either a finely granular, diffuse cytoplasmic staining or a coarsely granular, more localized staining in the cytoplasm. (Original magnification x400).

Discussion

During the patient's entire hospitalization at UH, the clinic did not make necessary diagnostic measures to detect that the patient had, in fact, a chronic infection by three hepatotropic viruses: HBV, HCV and HDV, only documented by the positive serology for HBV during his last days of life, and later confirmed by the IHC staining of the liver tissue taken at autopsy (Figure 1). All treatment efforts through the whole hospitalization period were based on the erroneous concept of alcohol being

the sole etiological factor, labeling the disease as ALD without confirmation by liver biopsy. Intensive state-of-art care with specific treatment strategies (e.g., antiviral therapy/MARS/hemodialysis/RRT)[1-6, 21-23] were, therefore, not carried out because of this unfortunate misconception on ALD in both CH and UH.

In clinical practices, inclusions and exclusions of extensive treatment activities, like RRT, are to be based on correct diagnosis and on correct knowledge of etiology of the liver damage. These considerations certainly failed in the present case. The accurate record of the potentially toxic drugs prescribed to the patients was ignored, while entirely focusing on alcohol and the possibility of a chronic latent viral hepatitis was disregarded.

Undeniably, the patient had occasional problems with alcohol, albeit not of such a severity as was recorded in the official documents, describing an intake of even up to 4 bottles of white wine per day for several years. This is incompatible with the fact that the patient continued his clinical practice as successful chiropractic until the hospitalization. Given that this record became an orthodox fact in all clinical decision-making, the considerations of other potential causes of liver damage were overlooked. Concerning the search for viral hepatitis, the testing at CH and UH was limited to one serological testing (HBsAg and HCAb) at the hospital entry alone. These tests may not adequately exclude the possibility of latent viral infections, and a single test will not provide information of possible reactivation of latent infection during later hospitalization periods [19,21-23]. In addition, the patient was obese, used polypharmacy (detailed records were available), including strong painkillers and synthetic opioids. In addition to alcohol, these are factors to be considered as potential causes of liver damage [24]. Daily cocktail of at least 10 prescriptions also included Tonalin® CLA Strong which is known for its liver toxicity [15-17].

According to properly verified past history, the patient spent several months in India 13 years earlier (in 1998), this area being known as one of the high-risk regions with remarkable change of contracting viral hepatitis of both B and C type [7-9]. At first admission to CH, this knowledge was not adequately recorded (i.e., "no trips abroad"), and these data were never controlled in UH.

The serological tests for viral hepatitis were negative at hospital entry on November 3rd but positive (HBsAb) a few days before the patient died in the UH abroad. This suggests a reactivation of latent viral hepatitis after November 3, acquired as potential co-infection with HBV and HCV in India 13 years earlier. The time lag (13 years) from the possible viral exposure in India matches well with the known natural history of the hepatitis-to-cirrhosis sequence [19]. The possibility of viral hepatitis that was unquestionably demonstrable in the autopsy liver samples by IHC, was missed in all levels of clinical decision making at CH and UH, where the patient's liver disease was treated as an ALD.

The sticking to ALD as the cause of the patient's liver damage led to conservative decisions in the treatment

strategy. Confirming the latent viral hepatitis and targeting the interferon-DAA treatment to viral infection could have arrested the progression of HRS. Instead, a treatment with steroids was instituted in both CH and UH, being contraindicated and extremely hazardous in viral hepatitis [13,14]. The patient did not receive medication with interferon or DAA either [7,8,21-23]. Finally, the tagging of diagnosis to ALD led also to exclusion of liver transplantation. This was accompanied by decisions to refrain from active care of HRS (intense care, MARS and hemodialysis) as the bridge therapy to liver transplantation, if ultimately even needed after an adequate therapy. This strategy was (augmented by steroids) accompanied with a rapid downhill course of fulminant HRS and fatal outcome in less than two months.

Lessons to learn

An accurate record of the patient's medical history and exploration of potential risk factors

This requirement applies particularly to the primary hospital entry failing to record regular medication, travels abroad, and use of liver-toxic food supplements. Thus, a critical part of the patient's history data was misleading, insufficiently recorded and inadequately controlled at all steps. Patient had used polypharmacy for years including strong painkillers (e.g. opiates) for severe hip arthrosis.

The daily use of a food supplement (Tonalin® CLA Strong) was not recorded. This product, classified as food supplement, contains conjugated linoleic acids (CLA), which has become increasingly popular for its beneficial effects, most notably due to its capacity to reduce body fat [15]. Apart from these beneficial effects of CLA, also safety concerns have been presented. The toxic effects of CLA in the liver are documented in a recent meta-analysis [15] based on the literature published since the 1990's, including case reports where fulminant liver failure (leading to transplantation) resulted even after short courses of CLA intake [16,17].

Liver biopsy as integral part of the diagnosis - also in alcoholic hepatitis/cirrhosis

Histopathological examination of liver biopsy enables opportunities for distinction between toxic reaction due to drugs, fatty liver (steatosis) due to obesity/alcohol intake, etiology of liver cirrhosis, and importantly, for detection of active and latent viral hepatitis and typing of the hepatitis virus (HBV, HCV or HDV), using the IHC for these viruses at the pathology laboratory.

While refusing to take the liver biopsy, the physicians failed to follow the European Guidelines for diagnosis of alcoholic liver disease (ALD) [25]. These Guidelines were elaborated during 2011, based on topics addressed in the EASL Monothematic Congress on ALD, held in Athens (Greece) December 10-12, 2010. In these Guidelines, it is clearly stated that histological diagnosis of ALD requires liver biopsy [25,27]. It can be done percutaneously in most patients, but may require a trans-jugular approach in patients with a low platelet count and/or a prolonged

prothrombin time [26]. Even if precise indications of liver biopsy are not established for routine practice, the biopsy is indicated in all patients with aggressive and fatal forms of ALD, i.e., in such diseases that require specific therapies (e.g. corticosteroids and/or pentoxifylline) [25].

In ALD, a liver biopsy also allows the clinicians to estimate the probability of long-term survival of the patients [27]. In this particular case, a liver biopsy would have solved the apparent discrepancy between a) the adopted clinical diagnosis of end-stage liver cirrhosis, and b) the large liver seen in the ultrasound examinations at UH. As generally known, end-stage cirrhosis leads to a shrinkage of the liver [19], usually weighting 500-600 g, but never 2800 g as subsequently shown in the autopsy. Given that 80% of the liver can be surgically resected without losing its capacity to regenerate, there were all reasons to believe that this enlarged liver still had a plenty of its regenerative capacity left. In fact, this conclusion (i.e., the liver might be potentially responsible to corticosteroid therapy) was reached on the bases of the ultrasound taken at UH (December 20th), in which the liver was large and nodular. However, the logical next step at this stage would have been to perform liver biopsy to confirm whether or not such a regenerative capacity is left, instead of reinstating the corticosteroid therapy, with a blind confidence on the ALD diagnosis.

HBV, HCV, HDV – a common combination in viral hepatitis

Worldwide, 400 million people suffer from chronic viral hepatitis B (HBV) and up to 170 million are affected by hepatitis C (HCV) [28,29]. In addition, 15-20 million individuals are estimated to be anti-HDV positive worldwide [30]. These infections account largely for the most chronic and end-stage liver diseases here and HBV alone is estimated to cause 1 million deaths annually [31]. Co-infections with hepatitis viruses are not uncommon [28,29]. It is estimated that 10% of HBV-infected patients are co-infected with HCV [32] and 5% of hepatitis B surface antigen (HBsAg)-carriers additionally carry HDV [33]. Since HBV, HCV, and HDV share almost the same modes of transmission [34], infection with more than one virus is possible [35]. Therefore, dual and triple viral infections have been reported from various parts of the world [28-33,36,37]. Patients with dual infections do have a higher mortality rate than those with infection of one virus alone (10%) [28,31]. Dual or triple infections with these hepatotropic viruses often lead to more severe liver damage and are known to increase the risk for hepatocellular carcinoma (HCC), up to 32% of the infected patients [38].

Not unexpectedly, co-infection with multiple viruses leads to management problems, which explain a higher mortality rate [28,31,34,39]. There are well documented reports in the literature, however, suggesting that standard dual therapy with peg-IFN α plus ribavirin can constitute a successful treatment in HCV/HBV/HDV-co-infected patients [28]

Viral hepatitis is treated with direct-acting antivirals (DAA) whereas corticosteroids are contraindicated

The medical treatment of viral hepatitis has undergone major progress starting from the use of interferons in the 1980's (7,8,21-23,40). Direct acting antivirals (DAAs) have led to cure rates of >95%, e.g., for HCV infections [40]. This represents a step forward from the era of peg-IFN α and ribavirin (RBV) (in the early 2000's) [28], which are still available treatment options today. When properly instituted, even multiple-type infections with HBV, HCV, HDV, can be successfully treated with different regimens of DAAs, IFN α and RBV as done for several years [28].

Corticosteroids have been a standard and accepted procedure in treating of ALD and HRS (1-6). However, steroid therapy in patients with viral hepatitis is hazardous and therefore strictly contraindicated. There is a plethora of reports warning that treating viral hepatitis (HBV or HCV) patients with steroids (e.g. methylprednisolone as was given to this patient) frequently leads to rapid reactivation of the latent virus, resulting in fulminant liver failure, HRS and death [13,14,41-48]. In our case, the steroid treatment was started in CH at the beginning of the patients' hospitalization, discontinued for a while but then restarted in the UH clinic. This parallels, at least in part, with the records of the patient clinical condition during the last 2 months. At transfer to UH (Dec 6th) the patient was in poor condition but improved during the period when steroids were discontinued. Once the steroids were restarted at UC on December 17, the condition rapidly deteriorated, resulting in fast downhill course and in transport (Dec 22nd) of the patient to another hospital in a moribund condition.

Conclusions

In light of the autopsy findings, it is feasible to consider that the rapid downhill course of HRS was attributable to two things acting synergistically in the present patient: 1) corticosteroids (started in CH) most likely activated the latent viral infection and accelerated the replication of HBV, HCV and HDV in the liver cells, resulting in severe acute-on-chronic fulminant hepatitis (13,14,41-48); 2) the patient did not receive adequate medical treatment for his viral hepatitis [7,8,21,23,28,40].

References

1. Ginès P, Schrier RW. Renal failure in cirrhosis. *N Engl J Med.* 2009;361:1279-1290. DOI: 10.1056/NEJMra0809139
2. Ginès P, Guevara M, Arroyo V, Rodés J. Hepatorenal syndrome. *Lancet.* 2003;362(9398):1819-1827.
3. Wadei HM, Mai ML, Ahsan N, Gonwa TA. Hepatorenal syndrome: pathophysiology and management. *Clin J Am Soc Nephrol.* 2006;1(5):1066-1079.
4. Arroyo V, Fernández J. Management of hepatorenal syndrome in patients with cirrhosis. *Nat Rev.* 2011;7:517-526. doi:10.1038/nrneph.2011.96

5. Caracenia P, Santia L, Miricia F, Montanaria G, Bevilacqua V, Pinnab AD, et al. Long-term treatment of hepatorenal syndrome as a bridge to liver transplantation. *Digest Liver Dis.* 2011;43(3):242-245. doi: 10.1016/j.dld.2010.08.001
6. Davenport A, Ahmad J, Al-Khafaji A, Kellum JA, Genyk YS, Nadim MK. Medical management of hepatorenal syndrome. *Nephrol Dial Transplant.* 2012;27(1):34-41.
7. Peters M, Davis GL, Dooley JS, Hoofnagle JH. The interferon system in acute and chronic viral hepatitis. *Prog Liver Dis.* 1986;8:453-467.
8. Bahcecioglu IH, Sahin A. Treatment of Delta hepatitis: Today and in the future - A review. *Infect Dis (Lond).* 2017;49(4):241-250. doi: 10.1080/23744235.2016.1271998
9. Krajden M, McNabb G, Petric M. The laboratory diagnosis of hepatitis B virus. *Can J Infect Dis Med Microbiol.* 2005;16(2):65-72.
10. Dufour DR. Hepatitis B surface antigen (HBsAg) assays-are they good enough for their current uses? *Clin Chem.* 2006;52(8):1457-1459.
11. Bottero J, Boyd A, Gozlan J, Lemoine M, Carrat F, Collignon A, et al. Performance of rapid tests for detection of HBsAg and anti-HBsAb in a large cohort, France. *J Hepatol.* 2013;58(3):473-478. doi: 10.1016/j.jhep.2012.11.016
12. Valentine-Thon E. Quality control in nucleic acid testing-where do we stand? *J Clin Virol.* 2002;25:Suppl 3:S13-21.
13. Magy N, Cribier B, Schmitt C, Ellero B, Jaeck D, Boudjema K, et al. Effects of corticosteroids on HCV infection. *Int J Immunopharmacol.* 1999;21(4):253-261.
14. Fong TL, Valinluck B, Govindarajan S, Charboneau F, Adkins RH, Redeker AG. Short-term prednisone therapy affects aminotransferase activity and hepatitis C virus RNA levels in chronic hepatitis C. *Gastroenterol.* 1994;107(1):196-199.
15. Mirzaei S, Mansourian M, Derakhshandeh-Rishehri SM, Kelishadi R, Heidari-Beni M. Association of conjugated linoleic acid consumption and liver enzymes in human studies: A systematic review and meta-analysis of randomized controlled clinical trials. *Nutrition.* 2016;32(2):166-173. doi: 10.1016/j.nut.2015.08.013
16. Ramos R, Mascarenhas J, Duarte P, Vicente C, Casteleiro C. Conjugated linoleic acid-induced toxic hepatitis: first case report. *Dig Dis Sci.* 2009;54(5):1141-1143. doi: 10.1007/s10620-008-0461-1
17. Nortadas R, Barata J. Fulminant hepatitis during self-medication with conjugated linoleic acid. *Ann Hepatol.* 2012;11(2):265-267.
18. WHO. WHO standards on reporting clinical trial results. 2017.
19. Busch K, Thimme R. Natural history of chronic hepatitis B virus infection. *Med Microbiol Immunol.* 2015;204(1):5-10.
20. Syrjänen S, Naud P, Sarian L, Derchain S, Roteli-Martins C, Tatti S, et al. Up-regulation of lipocalin 2 is associated with high-risk human papillomavirus and grade of cervical lesion at baseline but does not predict outcomes of infections or incident cervical intraepithelial neoplasia. *Am J ClinPathol.* 2010;134(1):50-59. doi: 10.1309/AJCP90IKJNQLSNRB
21. Public health agency of Canada. Primary Care Management of Hepatitis B – Quick Reference (HBV-QR). Canada.
22. Marcellin P, Asselah T, Boyer N. Treatment of chronic hepatitis B. *J Viral Hepat.* 2005;12(4):333-345.
23. Mir F, Kahveci AS, Ibdah JA, Tahan V. Sofosbuvir/velpatasvir regimen promises an effective pan-genotypic hepatitis C virus cure. *Drug Des Devel Ther.* 2017;11:497-502. doi: 10.2147/DDDT.S130945
24. Della Corte C, Mazzotta AR, Nobili V. Fatty liver disease and obesity in youth. *Curr Opin Endocrinol Diabetes Obes.* 2016;23(1):66-71. doi: 10.1097/MED.0000000000000221
25. European Association for the Study of the Liver. EASL Clinical Practical Guidelines: Management of Alcoholic Liver Disease. *J Hepatol.* 2012;57(2):399-420. doi: 10.1016/j.jhep.2012.04.004
26. Keshava SN, Mammen T, Surendrababu NRS, Moses V. Transjugular liver biopsy: What to do and what not to do? *Indian J Radiol Imaging.* 2008;18(3):245-248.
27. Naveau S, Gaude G, Asnacios A, Agostini H, Abella A, Barri-Ova N. Diagnostic and prognostic values of noninvasive biomarkers of fibrosis in patients with alcoholic liver disease. *Hepatology.* 2009;49(1):97-105. doi: 10.1002/hep.22576
28. Koff RS. Risks associated with hepatitis A and hepatitis B in patients with hepatitis C. *J Clin Gastroenterol.* 2001;33(1):20-26.
29. Hartl J, Ott C, Kirchner G, Salzberger B, Wiest R. Successful treatment of HCV/HBV/HDV-coinfection with pegylated interferon and ribavirin. *Clin Pract.* 2012;10;2(3):e64.
30. Hadziyannis SJ. Review: hepatitis delta. *J Gastroenterol Hepatol.* 1997;12(4):289-298.
31. Gholamreza R, Shahryar S, Abbasali K, Hamidreza J, Abdolvahab M, Khodabardi K, et al. Seroprevalence of hepatitis B virus and its co-infection with hepatitis D virus and hepatitis C virus in Iranian adult population. *Indian J Med Sci.* 2007;61(5):263-268.
32. Liaw YF. Role of hepatitis C virus in dual and triple hepatitis virus infection. *Hepatol.* 1995;22(4):1101-1108.
33. Hadziyannis SJ. Review: hepatitis delta. *J Gastroenterol Hepatol.* 1997;12(4):289-298.
34. Riaz MN, Faheem M, Anwar MA, Raheel U, Badshah Y, Akhtar H, et al. PCR-Based molecular diagnosis of Hepatitis Virus (HBV and HDV) in HCV infected patients and their biochemical study. *J Pathog.* 2016;2016(2016):3219793. doi: 10.1155/2016/3219793
35. Liuand Z, Hou J. Hepatitis B virus (HBV) and hepatitis C virus (HCV) dual infection. *Int J Med Sci.* 2006;3(2):57-62.
36. Zuberi BF, Quraishy MS, Afsar S, Kazi LA, Memon AR, Qadeer R, et al. Frequency and comparative analysis of hepatitis D in patients seeking

- treatment for hepatitis B. *J Col Phys Surg Pakistan*. 2006;16(9):581-584.
37. Tsatsralt-Od B, Takahashi M, Nishizawa T, Endo K, Inoue J, Okamoto H. High prevalence of dual or triple infection of hepatitis B, C, and delta viruses among patients with chronic liver disease in Mongolia. *J Med Virol*. 2005;77(4):491-499.
38. Sangiovanni A, Prati GM, Fasani P. The natural history of compensated cirrhosis due to hepatitis C virus: a 17-year cohort study of 214 patients. *Hepatology*. 2006;43(6):1303-1310.
39. Lorenc B, Sikorska K, Stalke P, Bielawski K, Ziętkowski D. Hepatitis D, B and C virus (HDV/HBV/HCV) coinfection as a diagnostic problem and therapeutic challenge. *Clin Exp Hepatol*. 2017;3(1):23-27.
40. Kardashian AA, Pockros PJ. Novel emerging treatments for hepatitis C infection: a fast-moving pipeline. *Therap Adv Gastroenterol*. 2017;10(2):277-282.
41. Mori N, Imamura M, Takaki S, Araki T, Hayes NC, Aisaka Y, et al. Hepatitis C virus (HCV) reactivation by steroid therapy for dermatomyositis. *Intern Med*. 2014;53(23):2689-2693.
42. Kanzaki H, Takaki A, Yagi T, Ikeda F, Yasunaka T, Koike K, et al. A case of fulminant liver failure associated with hepatitis C virus. *Clin J Gastroenterol*. 2014;7(2):170-174.
43. Margarit C, Bilbao I, Castells L, Lopez I, Pou L, Allende E, et al. prospective randomized trial comparing tacrolimus and steroids with tacrolimus monotherapy in liver transplantation: the impact on recurrence of hepatitis C. *Transpl Int*. 2005;18(12):1336-1345.
44. Nagai H, Matsumaru K, Shiozawa K, Momiyama K, Wakui N, Shinohara M, et al. Disappearance of HCV after cessation of immunosuppression in a patient with ulcerative colitis and renal transplantation. *J Gastroenterol*. 2005;40(8):848-853.
45. Henry SD, Metselaar HJ, Van Dijck J, Tilanus HW, Van Der Laan LJ. Impact of steroids on hepatitis C virus replication in vivo and in vitro. *Ann N Y Acad Sci*. 2007;1110:439-447.
46. Calleja JL, Albillos A, Cacho G, Iborra J, Abreu L, Escartín P. Interferon and prednisone therapy in chronic hepatitis C with nonorgan-specific antibodies. *J Hepatol*. 1996;24(3):308-312.
47. Bahra M, Neumann UP, Jacob D, Langrehr JM, Neuhaus P. Repeated steroid pulse therapies in HCV-positive liver recipients: significant risk factor for HCV-related graft loss. *Transplant Proc*. 2005;37(4):1700-1702.
48. Hou JK, Velayos F, Terrault N, Mahadevan U. Viral hepatitis and inflammatory bowel disease. *Inflamm Bowel Dis*. 2010;16(6):925-932.